

# Radiofrequency-Based Plasma Microtenotomy Compared With Arthroscopic Subacromial Decompression Yields Equivalent Outcomes for Rotator Cuff Tendinosis

Ettore Taverna, M.D., Ferdinando Battistella, M.D., Valerio Sansone, M.D., Carlo Perfetti, M.D., and James P. Tasto, M.D.

---

**Purpose:** This study aimed to determine whether radiofrequency (RF)-based plasma microtenotomy (microdebridement) was effective for treating chronic supraspinatus tendinosis. **Methods:** The institutional ethics committee approved the study design, and all patients signed informed consent forms. Patients (age range, 30 to 70 years) were considered for enrollment if 6 months of active conservative treatment had failed and they had Neer stage II impingement syndrome, positive radiographic evidence of type II acromion, and magnetic resonance imaging or ultrasound evidence of supraspinatus tendinosis. Patients (N = 60) were randomly assigned to undergo arthroscopic subacromial decompression or RF-based plasma microtenotomy. For microtenotomy, a bipolar RF-based probe (TOPAZ; ArthroCare, Austin, TX) was used to perform microdebridement in the supraspinatus tendon; patients did not undergo acromioplasty. Outcomes evaluation consisted of self-reported pain via a visual analog scale, as well as functional assessment (American Shoulder and Elbow Surgeons [ASES] survey, Constant score, and University of California, Los Angeles [UCLA] questionnaire). Statistical analyses were performed by use of factorial dependent-measures analysis of variance tests. **Results:** Age and baseline scores on the visual analog scale (mean  $\pm$  SD) were  $52.0 \pm 6.7$  and  $53.2 \pm 6.6$  years and  $8.4 \pm 0.9$  and  $8.2 \pm 0.8$  points in the microtenotomy and arthroscopic subacromial decompression groups, respectively. A significant reduction in pain ( $P < .001$ ) and improved function ( $P < .001$  for all measures) were observed in both groups postoperatively. Both treatment groups had almost identical longitudinal recovery profiles for pain relief ( $P = .416$ ) and restoration of function ( $P = .964$  for ASES score,  $P = .978$  for Constant score, and  $P = .794$  for UCLA score). At 1 year, the median pain score was 1.0, and all patients had ASES, Constant, and UCLA scores of greater than 90, greater than 80, and greater than 30, respectively. **Conclusions:** Both procedures were associated with significant improvement postoperatively, but the RF-based plasma microtenotomy procedure draws into question the need for a more extensive procedure such as subacromial decompression in this patient population. **Level of Evidence:** Level I, therapeutic randomized controlled study. **Key Words:** Arthroscopic subacromial decompression—Bipolar radiofrequency—Tendon debridement—Shoulder surgery—Microdebridement—Microtenotomy—Plasma.

---

---

From the Istituto Ortopedico Galeazzi (E.T., F.B., V.S., C.P.), Milan, Italy, and San Diego Sports Medicine and Orthopedic Center (J.P.T.), San Diego, California, U.S.A.

J.P.T. is on the Scientific Advisory Board of ArthroCare, Austin, Texas. The other authors report no conflict of interest.

Presented at the Annual Meeting of the Arthroscopy Association of North America, Hollywood, Florida, May 18-21, 2006.

Address correspondence and reprint requests to Ettore Taverna, M.D., Istituto Ortopedico Galeazzi, Via R Galeazzi, 4, 20161 Milan, Italy. E-mail: [ettore.taverna@fastwebnet.it](mailto:ettore.taverna@fastwebnet.it)

© 2007 by the Arthroscopy Association of North America  
0749-8063/07/2310-6516\$32.00/0  
doi:10.1016/j.arthro.2007.04.018

Anterior acromioplasty has long been accepted as a procedure of choice for performing subacromial decompression to treat chronic impingement syndrome in the shoulder.<sup>1</sup> In 1972 Neer<sup>2</sup> hypothesized that chronic impingement syndrome was due to the coracoacromial ligament and the anterior portion of the acromion impinging on the rotator cuff, producing pain and symptoms. He suggested removing the anterior edge and undersurface of the anterior aspect of the acromion and resecting the attached coracoacromial ligament (anterior acromioplasty procedure) as a surgical measure for relieving symptoms.<sup>2</sup> With the advent of shoulder arthroscopy, Ellman<sup>3</sup> observed 88%

success at 1 to 3 years using Neer's technique for arthroscopic subacromial decompression (ASAD) in patients with advanced stage II impingement without rotator cuff tear. Cordasco et al.<sup>4</sup> reported excellent clinical results in patients with partial-thickness tears of the rotator cuff comprising less than 50% of the tendon (grade 1 and 2) and acceptable clinical results in patients with grade 2B partial tears followed up for 2 to 10 years.

More recently, speculation surrounding the etiology of chronic impingement syndrome suggests that rotator cuff failure may occur first, precipitating secondary findings of impingement.<sup>1,5-7</sup> Nirschl and colleagues<sup>6,11-13</sup> have suggested that the terms "impingement syndrome," "bursitis," and "tendinitis" do not adequately capture the mechanical and histologic components of this condition and should be replaced with the more accurate term of "tendinosis," with effective treatment encompassing targeting of the underlying histopathology.<sup>8</sup>

Past research in our laboratory at the University of California, San Diego showed that angiogenic markers such as  $\alpha_v$  integrin and vascular endothelial growth factor are reduced in chronically injured degenerated tendons.<sup>14</sup> Low-dose radiofrequency (RF)-based plasma microtenotomy has the ability to stimulate angiogenic growth factors in tendon,<sup>15</sup> a response known to be associated with healing. Evaluation of this approach in a prospective controlled laboratory study using a rabbit tendon model showed histologic evidence of early inflammation with subsequent development of neovasculature after treatment.<sup>15</sup> A later histologic study using an aged Achilles rabbit tendon model was performed to evaluate the effect of RF-based plasma microtenotomy on collagen remodeling.<sup>16</sup> The degenerated tendon showed gaps, few normal crimpings, and a lack of reflectivity under polarized light. At 9 days after treatment, the treated tendon showed localized irregular crimpings, and at 30 days, it showed regular crimping, tightly dense collagen fibers, and hypercellularity with good reflectivity. This was similar in appearance to a normal nondegenerated tendon. A clinical study examining a prospective case series showed that the RF-based plasma microtenotomy approach is safe and effective through at least 2 years for alleviating symptoms associated with chronic tendinosis in the lateral elbow.<sup>17</sup>

The aim of this study was to determine whether RF-based plasma microtenotomy (microdebridement) was effective for treating chronic tendinosis of the supraspinatus tendon. This was a prospective, con-

trolled, double-blinded study in which patients with Neer stage II impingement syndrome received either ASAD or arthroscopic microtenotomy via a bipolar RF-based device. The device is designed to ablate (cut) very small segments of the tendon and leave the remainder intact, whereas a tenotomy generally consists of complete or near-complete resection of a tendon. The purpose of the study was to measure pain reduction and functional improvements through 1 year postoperatively in patients treated via arthroscopic RF-based plasma microtenotomy and to evaluate clinical outcomes as compared with a group of patients receiving a conventional ASAD.

## METHODS

### Study Design

Patients were randomly assigned to receive either arthroscopic RF-based plasma microtenotomy or ASAD. Both the patient and the postoperative evaluating physician were blinded to treatment. Clinical outcomes were collected at 6 weeks, 3 months, 6 months, and 1 year after the procedure and included visual analog scale (VAS) scores for pain; functional assessment via the American Shoulder and Elbow Surgeons (ASES) survey, the University of California, Los Angeles (UCLA) questionnaire, and the Constant score; and quality-of-life evaluation via the Short Form 36 (SF-36) tool. The Ethics Committee of Istituto Ortopedico Galeazzi, Milan, Italy, approved the study design. All patients signed informed consent forms.

### Patients

Patients aged between 30 and 70 years presenting to the clinic with symptoms consistent with tendinosis in the supraspinatus tendon associated with subacromial impingement were considered for inclusion into the study. A primary indication for surgery was that shoulder pain interfered with normal daily activities and affected sleep. The individual VAS pain score had to be 5 or greater, on a scale of 0 to 10, and in all patients a minimum of 6 months of conservative treatment had failed, including any combination of the following: physical therapy (including range of motion and strengthening), subacromial corticosteroid injection(s), nonsteroidal anti-inflammatory drug administration, activity modification, rest, and ice.

Patients had positive findings of impingement as measured by use of the Hawkins-Kennedy test or impingement sign test. A positive Hawkins-Kennedy

test was present if the patient had pain and apprehension when the examiner internally rotated a 90° forwardly flexed arm. A positive impingement sign test consisted of pain being produced while the examiner maximally forward flexed and internally rotated the patient's shoulder with one hand and exerted downward pressure on the acromion with the other hand. All patients included in the study also had a positive impingement test and positive supraspinatus isolation test (i.e., the empty-can or Jobe test). For a positive impingement test, pain was not reproduced during forward flexion and internal rotation after injection of 10 mL of 1% lidocaine into the subacromial space. For a positive supraspinatus isolation test, weakness was detected (compared with the unaffected arm) while the patient rotated the upper extremities so that the thumbs were pointing toward the floor and resistance was applied with the arms in 30° of forward flexion and 90° of abduction. Patients had evidence of tendinosis on magnetic resonance imaging (MRI) and type II acromion and impingement syndrome on radiography.

During arthroscopy, the clinical findings were confirmed noting Neer stage II (fibrosis and tendinitis) impingement syndrome. This may have included bursal-sided rotator cuff irregularity or abrasion resulting from the impingement process. Small partial-thickness tears that would not normally be treated surgically were not treated. Patients were not included in this study if they had primary instability of the shoulder secondarily leading to impingement, Neer stage I (edema and hemorrhage) impingement, full-thickness or substantial partial-thickness tears of the labrum or rotator cuff as shown by MRI or during arthroscopy, or significant ossification or calcification of the coracoacromial ligament or if they had undergone prior operative treatment for shoulder impingement.

Patients were randomly assigned to either undergo ASAD ( $n = 30$ ) or RF-based plasma microtenotomy ( $n = 30$ ) via a blinded envelope technique immediately before surgery. All patients underwent surgery between December 2003 and June 2004.

### **Surgical Procedures**

The same surgeon (E.T.) performed all procedures. The patient was placed in the beach-chair position, with no traction applied to the forearm. The extremity was prepped and draped in the usual sterile fashion. Glenohumeral arthroscopy was performed to evaluate concurrent pathology and to assess the undersurface of the rotator cuff. A lateral portal was created just an-

terior to the midpoint of the acromion and 3 to 4 cm lateral to the bony edge to allow passage of the arthroscope and a 7-mm cannula into the subacromial space, parallel to the acromial undersurface. The arthroscope was introduced through the posterior portal, just beneath the acromial surface, and out the anterior portal cannula for outflow anteriorly. Instruments were delivered posterolaterally into the subacromial space.

### **Subacromial Decompression**

ASAD was performed as reported by Ellman<sup>3</sup> and comprised coracoacromial ligament release, resection of the undersurface of the anterior acromion (anterior margin and lateral corner of the acromion), and complete debridement of the bursa. After the surgeon had performed the bursectomy and exposed the supraspinatus tendon, the bony undersurface of the acromion was cleared of soft tissue with a full-radius shaver until the bony anterolateral corner, anteromedial corner, and anterior margin of the acromion were visible. A 4.5-mm-diameter barrel bur was used to perform the bone resection, where approximately 0.5 cm of bone was removed. Any osteophytes and ossified sections of the coracoacromial ligament were also removed. The ligament itself was resected from the anteroinferior aspect of the anterior margin (to clearly see the anterior edge of the acromion) but was not detached from the acromion.

### **RF-Based Plasma Microtenotomy**

In the patients who underwent the RF-based plasma microtenotomy, the objective was to remove only as much of the bursa as required to be able to see the tendon clearly. However, the extent of the bursectomy was determined on a case-by-case basis, and as much of the bursa was removed as was necessary in each case. A bipolar RF-based device (TOPAZ microdebrider; ArthroCare, Austin, TX) connected to a System 2000 generator (ArthroCare) was used to perform the microtenotomy.

The device was inserted into the lateral portal and placed on the tendon perpendicular to its surface. The area of the tendon treated was the preinsertional area that generally showed a change toward being more yellowish in color than normal and was of softer consistency upon palpation with a probe and correlated to the MRI or ultrasound location of the tendinosis. Using a light touch, the surgeon activated the device (using controller setting 4), for 500 milliseconds, and microdebridements were performed at

5-mm intervals, at a depth 3 to 5 mm, to create a 3-dimensional grid-like pattern throughout the affected tendon area.

The bipolar RF-based device used in the study functions via a controlled RF-based plasma process. In this process RF energy is used to excite the water molecules in a conductive medium, such as an electrolyte (saline) solution, to generate excited radicals within a precisely focused plasma. The energized particles in the plasma have sufficient energy to break molecular bonds,<sup>18-20</sup> excising or dissolving (i.e., ablating) soft tissue at relatively low temperatures (typically 40°C to 70°C). The feature that differentiates this technology from other systems, including other RF devices, is the formation of a glow discharge that is the mediator of the treatment, not the RF or the heat that it produces. Therefore this technology is an RF-based technique, but its mechanism of action is a chemical process<sup>20</sup> and not a function of the RF energy itself. The tip of the TOPAZ device is about 0.8 mm in diameter and has a surface area of 0.502 mm<sup>2</sup>. On the basis of the assumption that the mean depth for each microdebridement is 4 mm, each perforation would remove about 2 mm<sup>3</sup> of tissue. A typical rotator cuff microtenotomy procedure consists of 7 to 25 microdebridements (removing 14 to 50 mm<sup>3</sup> of tissue), depending on the patient.

### Care After Procedures

All patients were discharged on the same day or the morning after the procedure. Both groups underwent the same rehabilitation protocol. One to two days after the procedure, patients began passive range-of-motion exercises. Between the first and second postoperative month, patients started an exercise program designed to strengthen the rotator cuff and other scapular girdle muscles.

### Outcome Measures and Follow-up

Clinical outcome measures included assessment of shoulder pain via a VAS score; evaluation of shoulder function via UCLA, Constant, and ASES scores; and quality-of-life assessment via the SF-36. All outcome measures were collected before the procedure and at 6 weeks and 3, 6, and 12 months postoperatively. The clinician performing all postoperative patient evaluations was blinded to the surgical treatment.

The VAS scale used in the study was administered immediately before the procedure (baseline) and at all postoperative visits. The VAS was a horizontal 10-cm line with word anchors at the extremes: “no pain” on

the left end and “worst pain imaginable” on the right end. The patient was asked to make a mark along the line, ranking the amount of pain he or she had been having within the previous week. The score was obtained by measuring the distance from the left end up to the point that the patient marked (in centimeters).

The ASES score is a global index consisting of the following components: shoulder range of motion, function, stability, strength, pain, and ability to perform activities of daily living.<sup>21,22</sup> The patient self-evaluation section has 11 items that can be used to generate a score. These are divided into 2 areas: pain (1 item) and function (10 items). The pain item is collected via a 10-cm VAS, which is divided into 1-cm increments and anchored with verbal descriptors at 0 and 10 cm. The 10 items of the function area include activities of daily living, strength assessment, and physical activity. The total possible score is 100 points. The UCLA shoulder assessment assigns a score to patients based on 5 separate domains: pain, function, strength, active forward flexion, and overall satisfaction.<sup>22</sup> The pain item accounts for 10 points; function, 10 points; forward flexion, 5 points; strength, 5 points; and overall satisfaction, 5 points; the total possible score is 35 points. The Constant scoring assessment consists of 4 components related to function of the shoulder: pain, disability, range of motion, and strength.<sup>22,23</sup> The subjective measures of pain and disability comprise 35 points, and the objective measures of range of motion and strength comprise 65 points, for a total possible score of 100 points. The subjective assessment includes a single item for pain (15 points) and 4 items for activities of daily living (20 points). The objective assessment includes range of motion (forward elevation, lateral elevation, internal rotation, and external rotation) and power.

The SF-36 is a patient-based health status assessment survey designed to assess the impact of medical problems across a broad spectrum of disease states on an individual's general sense of well-being.

### Study Power and Statistical Analyses

The sample size selected for this study was based on the tenets provided by the central limit theorem, which suggests that a sample size of 30 is generally considered to be satisfactory in most practical situations.<sup>24</sup> Statistical analyses were conducted via SPSS for Windows software (version 14.0; SPSS, Chicago, IL). The continuous variables were tested for normality and equal variance before statistical analyses. If normality and equal variance were achieved, then parametric

**TABLE 1.** Patient Demographics

	Microtenotomy (n = 30)	ASAD (n = 30)	P Value
Age (y)	52 ± 7 (36-65)	53 ± 7 (40-65)	.461
Gender (female)	21 (70%)	17 (57%)	.284
Surgical side (right)	19 (63%)	20 (67%)	.787
Preoperative pain score (VAS)	8 ± 1 (7-10)	8 ± 1 (7-10)	.470
Preoperative ASES score (points)	39 ± 3 (37-48)	39 ± 4 (25-45)	.314
20-30	1	0	
31-40	18	16	
41-50	11	14	
Preoperative UCLA score (points)	16 ± 2 (12-20)	17 ± 2 (12-20)	.510
10-15	9	7	
16-20	20	21	
21-25	1	2	
Preoperative Constant score (points)	51 ± 4 (40-61)	54 ± 11 (40-93)	.137
41-50	12	8	
51-60	17	19	
61-70	1	3	

NOTE. Data are presented as mean ± SD or number of patients. There are 100 points possible for the ASES score, 35 points for the UCLA score and 100 points for the Constant score.

analyses were used; if normality was not achieved, then a nonparametric test (e.g., Wilcoxon signed rank test) was applied. Categorical variables were analyzed by use of the  $\chi^2$  test or Fisher exact test. Statistical analyses to evaluate postoperative changes in pain and functional measures across time were performed via a factorial dependent-measures analysis of variance test. A minimum significance level of  $P \leq .05$  was set for all statistical tests.

## RESULTS

Both treatment groups were largely made up of women aged over 50 years (Table 1). Age, gender, and preoperative pain and functional assessment measures did not differ significantly between groups.

No significant operative or perioperative complications or events were observed. Postoperatively, both treatment groups showed significantly ( $P < .001$ ) reduced pain at the 10-day examination (Fig 1). The microtenotomy group showed a longitudinal profile similar to that of the ASAD group for pain reduction through the first year postoperatively ( $P = .480$ ). The number of patients reporting a VAS score of 1 or 0 at 3, 6, and 12 months was 1 (3%), 11 (37%), and 28 (93%), respectively, in both surgical groups.

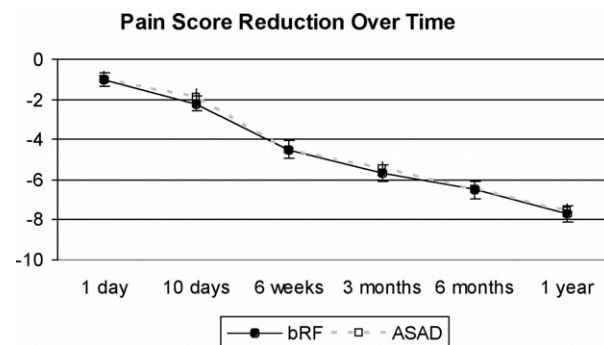
Both surgical groups had significantly improved functional scores at the 6-week examination (Figs 2-4). The microtenotomy group showed a longitudinal recovery profile similar to that of the ASAD group for improved function over the first year postoperatively

( $P = .964$  for ASES score,  $P = .978$  for Constant score, and  $P = .794$  for UCLA score). At 1 year, all patients had ASES, Constant, and UCLA scores of greater than 90, greater than 80, and greater than 30, respectively (Table 2).

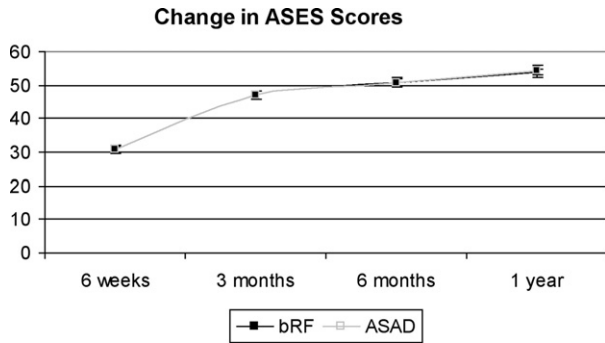
The quality-of-life scores through the first year postoperatively as measured by use of the physical functioning component assessed via the SF-36 were similar for both treatment groups (Fig 5).

## DISCUSSION

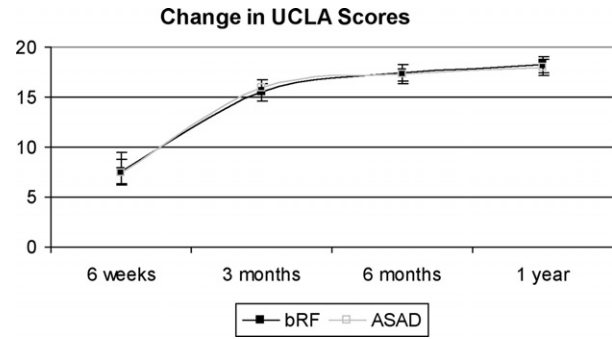
Both surgical procedures were associated with significant improvement from preoperative scores over



**FIGURE 1.** Postoperative changes in pain score (from preoperative scores) are shown across all examination time points through 1 year. The pain reduction profile was statistically similar ( $P = .416$ ) for both surgical treatment groups. (bRF, RF-based plasma microtenotomy.)



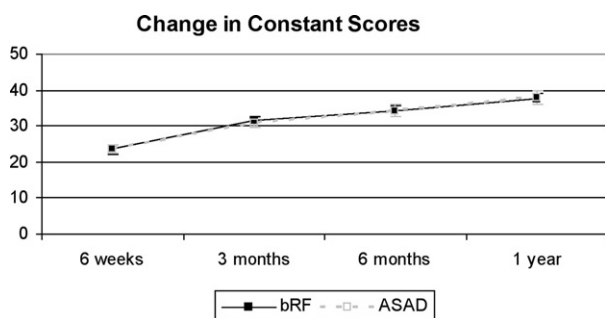
**FIGURE 2.** Postoperative changes in ASES scores (from preoperative scores) are shown across all examination time points through 1 year. Improvements in scores across time were statistically similar ( $P = .964$ ) for both surgical treatment groups. (bRF, RF-based plasma microtenotomy.)



**FIGURE 4.** Postoperative changes (from preoperative scores) in UCLA scores are shown across all examination time points through 1 year. Improvements in scores across time were statistically similar ( $P = .794$ ) for both surgical treatment groups. (bRF, RF-based plasma microtenotomy.)

the 1-year follow-up period. In no patient in either treatment group was surgery considered to have failed at 1 year. This study suggested that the RF-based plasma microtenotomy was capable of achieving a similarly beneficial clinical result to ASAD through the first year postoperatively. The RF-based plasma microtenotomy is a simpler and less involved procedure than ASAD and does not require bony resection, full bursectomy, or resection of the coracoacromial ligament. It therefore draws into question the need to conduct the more extensive conventional subacromial decompression in the population of patients selected for this study.

At 1 year, all patients in both treatment groups had ASES scores greater than 90, UCLA scores greater than 30, and Constant scores greater than 80. Past experience has generally indicated that 85% or greater success is achieved with ASAD.<sup>5</sup> In one of the earlier



**FIGURE 3.** Postoperative improvements (from preoperative scores) in Constant scores are shown across all examination time points through 1 year. Improvements in scores across time were statistically similar ( $P = .978$ ) for both surgical treatment groups. (bRF, RF-based plasma microtenotomy.)

studies evaluating ASAD, conducted in a patient sample consisting of 50 patients, 40 of whom had advanced stage II impingement without rotator cuff tear, Ellman rated 88% of cases as having excellent or good results at 1 to 3 years by use of the UCLA shoulder rating scale.<sup>3</sup> De Baere et al.<sup>24</sup> retrospectively evaluated a consecutive series of 13 patients who underwent arthroscopic acromioplasty for intractable pain associated with long-standing rotator cuff deficiency. The Constant-Murley score was improved from 59 (range, 40 to 90) preoperatively to 99 (range, 69 to 123) at a mean of 19 months (range, 12 to 42 months) postoperatively. In patients who had a standard open acromioplasty and resection of the subacromial bursa, McKee and Yoo<sup>25</sup> reported preoperative SF-36 scores of 37.6 points for the physical component summary for patients with no tear; at 24 months postoperatively, the SF-36 score was significantly increased to 45 points. Both treatment groups in our study had results that were at least as good as or better than those in the patients undergoing ASAD but not requiring rotator cuff repair reported in these previous studies. Our success rate after both RF-based plasma microtenotomy and ASAD coincided with clinical expectations.

Impingement is thought to occur as a result of the dysfunctional rotator cuff producing upward displacement of the humeral head, and with use of the shoulder, the humeral head causes impingement of the rotator cuff against the coracoacromial arch.<sup>1</sup> Recent advances in defining and understanding the histopathologic and ultrastructural characteristics of symptomatic chronic tendinopathy, such as that appearing to occur in the dysfunctional rotator cuff, have suggested that this pathology is a noninflammatory, degenerative condition.<sup>8-10</sup> Review of the literature

**TABLE 2.** Number of Patients in Each Treatment Group With ASES, UCLA, and Constant Function Scores at 3, 6, and 12 Months Postoperatively

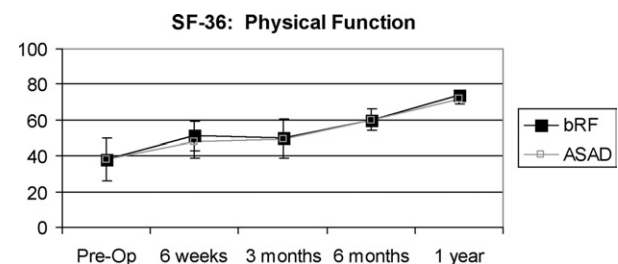
	3 Months		6 Months		12 Months	
	Microtenotomy	ASAD	Microtenotomy	ASAD	Microtenotomy	ASAD
ASES score						
>95	0	0	0	0	10	7
>90	5	0	24	15	30	30
>80	30	30	30	30	30	30
UCLA score						
34-35	7	10	20	22	28	30
>28	30	30	30	30	30	30
Constant score						
>90	0	0	5	5	16	19
>80	27	28	30	30	30	30
>70	30	30	30	30	30	30

describing the histopathology of sports-related symptomatic Achilles, patellar, extensor carpi radialis brevis, and rotator cuff tendons revealed that the chronically symptomatic tendon shows distinct signs of degeneration, such as gray appearance and histopathologic evidence of disorganized collagen fibers, increased fibrocartilaginous appearance, and absence of inflammation. These findings were believed to explain why tendinosis was frequently refractory to conventional conservative treatments.<sup>8</sup> Histopathologic, histochemistry, and morphologic signs in torn rotator cuff tendons revealed that tears were very likely to be a result of degenerative changes in the middle and deep layers of the tendon associated with micro-trauma.<sup>9</sup> Rees et al.<sup>10</sup> suggested that specific tendons such as the Achilles and supraspinatus tendons may be particularly prone to degenerative pathologic changes.

Patients with Neer stage II (fibrosis and tendinitis) impingement syndrome showing imaging evidence of tendinosis in the supraspinatus tendon responded well to the RF-based plasma microtenotomy and had a recovery profile through the first postoperative year similar to that of patients receiving ASAD. The results of this study lend support to the conclusions of previous investigators that rotator cuff dysfunction symptoms may be treated effectively by targeting the underlying histopathology of tendinosis.<sup>6,8,11-13</sup> Kyrola et al.<sup>26</sup> evaluated 28 patients aged  $55.8 \pm 7.6$  years using MRI 4.6  $\pm$  2.1 years after surgery for rotator cuff tear; the cuff tear was traumatic in 18 patients (64%) and degenerative in 10 patients (36%). A normal appearance of the rotator cuff correlated with good clinical outcomes, whereas retear and signs of tendinosis were associated with pain. Kartus et al.<sup>27</sup> tested the theory that performing debridement and

acromioplasty in patients with an Ellman type II partial rotator cuff tear would render good long-term results and prevent progression of degeneration to a full-thickness rotator cuff tear. They retrospectively evaluated 26 patients with a minimum follow-up of 5 years. The mean postoperative pain score, assessed via a VAS score, was 20 mm, ranging in severity from 0 to 85 mm. The Constant score after repair of the articular-sided tear was 72 (range, 35 to 97). Nine patients had ultrasound evidence of progression to a full-thickness tear during the follow-up period. The relatively poorer results in some patients led these investigators to conclude that an arthroscopic acromioplasty and rotator cuff debridement conducted in patients with partial tears did not protect the rotator cuff from undergoing further degeneration. These studies indicate that conventional ASAD may not adequately address the underlying rotator cuff pathology in some patients.

Other clinical investigators have assessed alternatives to the conventional acromioplasty procedure for



**FIGURE 5.** SF-36 scores plotted across time showed similar incremental improvement through 1 year postoperatively for both surgical treatment groups. (Pre-Op, preoperatively; bRF, RF-based plasma microtenotomy.)

treating patients showing symptoms consistent with rotator cuff tendinosis. In patients with partial-thickness articular-sided rotator cuff tears, treated via arthroscopic rotator cuff debridement without acromioplasty, where the procedure consisted of aggressive debridement of the affected tendon tissue with a motorized shaver, Budoff et al.<sup>6</sup> reported good and excellent results in 86% at a mean of 53.2 months' follow-up (range, 25 to 93 months). Longer-term evaluation of the same patient cohort at a mean of 114 months postoperatively showed an overall success rate of 79%. The 43 tears of less than 50% thickness preoperatively exhibited a higher success rate of 86%. Gartsman and O'Connor<sup>28</sup> evaluated the clinical effect of ASAD in patients with a type 2 acromion undergoing rotator cuff repair. With a minimum follow-up of 1 year, ASES shoulder scores did not differ significantly between the group of patients who received subacromial decompression and those who did not. These studies suggest that conventional subacromial decompression may not be imperative for improving pain relief and functional status in patients with impingement syndrome or who undergo rotator cuff repair.

The subacromial bursa in patients with a rotator cuff tear shows a significantly higher expression of inflammatory cytokines, tumor necrosis factor  $\alpha$ , metalloproteases, and cyclooxygenase enzymes than the bursa of patients who do not have a tear.<sup>29,30</sup> Arthroscopic subacromial bursectomy and calcium removal have been reported to provide a good alternative for treating chronic rotator cuff calcific tendinitis.<sup>31,32</sup> There is a possibility that the need to remove at least some of the bursa to clearly see the tendon in the microdebridement cases may have confounded our results because the bursa is known to possess pain mediators. However, in the patients who received the RF-based plasma microtenotomy, we aimed to remove as little of the bursa as possible, which in most cases consisted only of enough tissue to be able to clearly visualize the tendon. Because the microtenotomy patients did not undergo debridement of the entire subacromial space such as the ASAD patients received, we believe that any confounding effects of the bursectomy would be minimized by use of this approach; our approach appeared to be similar to that used by Budoff et al.<sup>6</sup> Nevertheless, in our study the extent of bursectomy was determined on a case-by-case basis and as much of the bursa was removed as we believed was necessary for visualization. It may have been beneficial to include a group of patients who received only bursectomy to evaluate its effects

on clinical response because it is not clear how strongly this part of the procedure may have affected postoperative outcomes. However, when this study was conducted, we were not comfortable performing bursectomy alone in this population of patients.

In patients receiving arthroscopic acromioplasty, De Baere et al.<sup>24</sup> reported significant postoperative improvement in pain and range of motion but not in strength. Cole et al.<sup>33</sup> tested the hypothesis that RF-based plasma debridement via a bipolar device enhanced the repair of chronic supraspinatus tendon tears by improving mechanical properties of the treated tendon using a rat rotator cuff model.<sup>34</sup> At 12 weeks, tendons that had received the bipolar RF-based plasma debridement were 4 times more likely than non-RF-treated tendons to fail by fracture, permitting significantly greater maximum stress than non-RF-treated tendons; at 8 weeks, the RF-treated tendons had a histologic appearance similar to controls. These investigators concluded that adjunctive RF-based plasma microdebridement appeared to enhance the biomechanical and histologic properties of tendon after repair. Biomechanical properties, including ultimate stress at failure, elastic modulus, strain energy density, and strain at maximum load, of human patellar tendons in a cadaveric model were not significantly affected in the acute phase after receiving RF-based plasma microdebridement.<sup>35</sup> In future studies it may be beneficial to rigorously evaluate strength of the treated structure independently, as opposed to simply relying on global indices such as the ASES, UCLA, and Constant-Murley assessments.

We detected no significant difference between treatment groups in clinical outcomes through 1 year. This finding could be attributed to two different conclusions: (1) there is no difference between these two treatments in this population of patients, or (2) the study was insufficiently powered to detect a significant difference. By use of the sample size estimation parameters reported by Gartsman and O'Connor,<sup>28</sup> post hoc evaluation of study power to show that the mean for the new treatment (microtenotomy) was equivalent to the active control (ASAD)—in which the null hypothesis tested was that the mean postprocedural clinical outcome scores for the microtenotomy group, as determined by use of the ASES questionnaire, would be no lower than those for the ASAD group at 12 months after the procedure—was conducted against the 1-sided alternative hypothesis. By estimating a common SD of 10 points for the postprocedural ASES scores and setting the type I error rate at 5%, a sample size of 30 subjects in each group

would have 85% power to detect a difference of 7 points between groups for the ASES score at 1 year postoperatively (SamplePower, version 2; SPSS). Post hoc evaluation of study power, given these parameters, suggests that this study had sufficient power to show equivalency of treatments.

Longer-term follow-up would be beneficial because significant differences between the two procedures may become apparent given more time. Past studies have indicated a mean time of greater than 24 months for patients with failed subacromial decompression to return for a secondary procedure.<sup>36-38</sup> In patients treated for Neer stage II impingement via subacromial decompression, 17% showed unsatisfactory UCLA scores at a mean of 32 months' follow-up.<sup>36</sup> Ellman<sup>3</sup> reported unsatisfactory results (UCLA score) in 12% of patients between 1 and 3 years after surgery. In patients who had received adequate decompression, Hawkins et al.<sup>38</sup> reported a failure rate of 14% at a mean follow-up of 56 months. Currently, we have no plans to continue observing the patients included in this study; however, at the time of this writing, all patients were in their third postprocedural year, and none had returned to the clinic for subsequent care.

## CONCLUSIONS

Use of RF-based plasma microtenotomy in patients with tendinosis as shown by MRI and type II acromion and impingement syndrome as shown by radiography suggested that pain and functional symptoms associated with this condition were successfully treated through 1 year. Clinical outcomes in this group of patients were equivalent to those in patients receiving a conventional ASAD.

**Acknowledgment:** The authors thank Debby Holmes-Higgin, M.S., M.P.H., for editing the manuscript and assisting with statistical analyses; Jean Woloszko, M.D., Ph.D., for technical assistance; and Wendy Winters, B.S., for assisting with study coordination.

## REFERENCES

1. Neer CS II. Anterior acromioplasty for the chronic impingement syndrome in the shoulder. 1972. *J Bone Joint Surg Am* 2005;87:1399.
2. Neer CS II. Anterior acromioplasty for the chronic impingement syndrome in the shoulder: A preliminary report. *J Bone Joint Surg Am* 1972;54:41-50.
3. Ellman H. Arthroscopic subacromial decompression: Analysis of one- to three-year results. *Arthroscopy* 1987;3:173-181.
4. Cordasco FA, Backer M, Craig EV, Klein D, Warren RF. The partial-thickness rotator cuff tear: Is acromioplasty without repair sufficient? *Am J Sports Med* 2002;30:257-260.
5. Nottage WM. Rotator cuff repair with or without acromioplasty. *Arthroscopy* 2003;19:229-232 (suppl 1).
6. Budoff JE, Rodin D, Ochiai DH, Nirschl RP. Arthroscopic rotator cuff debridement without decompression for the treatment of tendinosis. *Arthroscopy* 2005;21:1081-1089.
7. Budoff JE, Nirschl RP, Ilahi OA, Rodin D. Internal impingement in the etiology of rotator cuff tendinosis revisited. *Arthroscopy* 2003;19:810-814.
8. Khan KM, Cook JL, Bonar F, Harcourt P, Astrom M. Histopathology of common tendinopathies. Update and implications for clinical management. *Sports Med* 1999;27:393-408.
9. Hashimoto T, Nobuhara K, Hamada T. Pathologic evidence of degeneration as a primary cause of rotator cuff tear. *Clin Orthop Relat Res* 2003;111-120.
10. Rees JD, Wilson AM, Wolman RL. Current concepts in the management of tendon disorders. *Rheumatology (Oxford)* 2006;45:508-521.
11. Nirschl RP. Treatment of rotator cuff impingement. *Orthop Rev* 1993;22:1194.
12. Nirschl RP. Rotator cuff tendinitis: Basic concepts of pathoetiology. *Instr Course Lect* 1989;38:439-445.
13. Nirschl RP. Chronic rotator cuff tears. *Orthop Rev* 1986;15:758-759.
14. Medlock VB, Amiel D, Harwood F, Ball S, Tasto JP. Angiogenic response to bipolar radiofrequency treatment of normal rabbit achilles tendon. Presented at the International Society of Arthroscopy, Knee Surgery and Orthopaedic Sports Medicine Congress, Auckland, New Zealand, March 10-14, 2003.
15. Harwood F, Medlock B, Bowden K, Ball S, Tasto JP, Amiel D. Structural and angiogenic response to bipolar radiofrequency treatment of normal rabbit Achilles tendon: A potential application to the treatment of tendinosis. *Trans Orthop Res Soc* 2003;28:P0819.
16. Takahashi N, Tasto JP, Locke J, et al. The use of radiofrequency (RF) for the treatment of chronic tendinosis. Presented at the International Society of Arthroscopy, Knee Surgery and Orthopaedic Sports Medicine Congress, Florence, Italy, May 27-31, 2007.
17. Tasto JP, Cummings J, Medlock V, Hardesty R, Amiel D. Microtenotomy using a radiofrequency probe to treat lateral epicondylitis. *Arthroscopy* 2005;21:851-860.
18. Stalder KR, Woloszko J, Brown IG, Smith CD. Repetitive plasma discharges in saline solutions. *Appl Phys Lett* 2001;79:4503-4505.
19. Woloszko J, Stalder KR, Brown IG. Plasma characteristics of repetitively-pulsed electrical discharges in saline solutions used for surgical procedures. *IEEE Trans Plasma Sci* 2002;30:1376-1383.
20. Stalder KR, McMillen DF, Woloszko J. Electrosurgical plasmas. *J Phys D Appl Phys* 2005;38:1728-1738.
21. Michener L, McClure P, Sennett B. American Shoulder and Elbow Surgeons Standardized Shoulder Assessment Form, patient self-report section: Reliability, validity, and responsiveness. *J Shoulder Elbow Surg* 2002;11:587-594.
22. Kirkley A, Griffin S, Dainty K. Scoring systems for the functional assessment of the shoulder. *Arthroscopy* 2003;19:1109-1120.
23. Constant CR, Murley AH. A clinical method of functional assessment of the shoulder. *Clin Orthop Relat Res* 1987;160-164.
24. De Baere T, Dubuc JE, Joris D, Delloye C. Results of arthroscopic acromioplasty for chronic rotator cuff lesion. *Acta Orthop Belg* 2004;70:520-524.
25. McKee MD, Yoo DJ. The effect of surgery for rotator cuff disease on general health status. Results of a prospective trial. *J Bone Joint Surg Am* 2000;82:970-979.
26. Kyrola K, Niemitukia L, Jaroma H, Vaatainen U. Long-term

- MRI findings in operated rotator cuff tear. *Acta Radiol* 2004;45:526-533.
27. Kartus J, Kartus C, Rostgard-Christensen L, Sernert N, Read J, Perko M. Long-term clinical and ultrasound evaluation after arthroscopic acromioplasty in patients with partial rotator cuff tears. *Arthroscopy* 2006;22:44-49.
  28. Gartsman GM, O'Connor DP. Arthroscopic rotator cuff repair with and without arthroscopic subacromial decompression: A prospective, randomized study of one-year outcomes. *J Shoulder Elbow Surg* 2004;13:424-426.
  29. Voloshin I, Gelinas J, Maloney MD, O'Keefe RJ, Bigliani LU, Blaine TA. Proinflammatory cytokines and metalloproteinases are expressed in the subacromial bursa in patients with rotator cuff disease. *Arthroscopy* 2005;21:1076.e1-1076.e9. Available online at [www.arthroscopyjournal.org](http://www.arthroscopyjournal.org).
  30. Blaine TA, Kim YS, Voloshin I, et al. The molecular pathophysiology of subacromial bursitis in rotator cuff disease. *J Shoulder Elbow Surg* 2005;14:84S-89S.
  31. Ark JW, Flock TJ, Flatow EL, Bigliani LU. Arthroscopic treatment of calcific tendinitis of the shoulder. *Arthroscopy* 1992;8:183-188.
  32. Ozkoc G, Akpinar S, Hersekli MA, Ozalay M, Tandogan RN. Arthroscopic treatment of rotator cuff calcifying tendinitis. *Acta Orthop Traumatol Turc* 2002;36:413-416 (in Turkish).
  33. Cole BJ, Lin JL, Carreira DS, et al. Bipolar radiofrequency energy enhanced repair of chronic supraspinatus tears in rats. Presented at the Annual Meeting of the American Academy of Orthopedic Surgeons, Washington, DC, February 23-27, 2005.
  34. Gartsman GM, Hasan SS. What's new in shoulder and elbow surgery. *J Bone Joint Surg Am* 2006;88:230-243.
  35. Silver WP, Creighton RA, Triantafillopoulos IK, Devkota AC, Weinhold PS, Karas SG. Thermal microdebridement does not affect the time zero biomechanical properties of human patellar tendons. *Am J Sports Med* 2004;32:1946-1952.
  36. Burns TP, Turba JE. Arthroscopic treatment of shoulder impingement in athletes. *Am J Sports Med* 1992;20:13-16.
  37. Connor PM, Yamaguchi K, Pollock RG, Flatow EL, Bigliani LU. Comparison of arthroscopic and open revision decompression for failed anterior acromioplasty. *Orthopedics* 2000;23:549-554.
  38. Hawkins RJ, Plancher KD, Saddemi SR, Brezenoff LS, Moor JT. Arthroscopic subacromial decompression. *J Shoulder Elbow Surg* 2001;10:225-230.